



Non-functional parathyroid cyst – diagnostic pitfall: A case-report

Nefunkcionalna cista paratiroidne žlezde – dijagnostička zamka

Snežana P. Polovina*[†], Zoran Andjelković[‡], Dragan D. Micić*[†]

*Clinic for Endocrinology, Diabetes and Diseases of Metabolism, Clinical Center of Serbia, Belgrade, Serbia; [†]Faculty of Medicine, University of Belgrade, Belgrade, Serbia;

[‡]Clinic for Endocrinology, Military Medical Academy, Belgrade, Serbia

Abstract

Introduction. Parathyroid cysts are relative rare and they may be misdiagnosed with thyroid nodules. Parathyroid cysts are characterized by elevated level of parathyroid hormone (PTH) in cystic fluid. **Case report.** We reported about middle-aged woman with palpable node in the left thyroid lobe. Ultrasound showed anechoic 40 × 25 mm lesion in the left thyroid lobe. Fine needle aspiration (FNA) obtained 13 mL colorless, watery cystic fluid. PTH value in cystic fluid was ten fold more in comparison with serum PTH. Serum PTH was slightly elevated, D vitamin was under the reference range, serum calcium and phosphorus were normal as well as thyroid hormones. Thyroglobulin antibodies (TgAb) and thyroid peroxidase antibodies (TPOAb) were not detected. Radionuclide parathyroid scintigraphy indicated at physiological metaiodobenzyl-guamide (MIBG) distribution. After six months of vitamin D supplementation, serum calcium, phosphorus, vitamin D and PTH were normal. This finding was indicative that was a nonfunctional parathyroid cyst. **Conclusion.** This case report points out that thyroid cystic lesions with thin walls, and reverberation in ultrasound, must be observed as a potential parathyroid cyst. These cysts require caution during diagnostic aspiration because of danger of hypercalcemic crises due to FNA, which can be a life-threatening condition.

Key words:

parathyroid diseases; cysts; biopsy, fine needle; hypercalcemia.

Apstrakt

Uvod. Paratiroidne ciste relativno su retke i mogu da izgledaju kao koloidno degenerisani čvorovi u štitastoj žlezdi. Za paratiroidne ciste karakterističan je povišen nivo paratiroidnog hormona (PTH) u cističnoj tečnosti. **Prikaz bolesnika.** Prikazali smo sredovečnu ženu sa palpabilnim čvorom u levom režnju štitaste žlezde. Ultrazvučnim preglednom ustanovljena je anehogena, ovalna promena 40 × 25 mm. Aspiracijom je dobijeno 13 mL bezbojne, bistre tečnosti. PTH u cističnoj tečnosti bio je desetstruko viši u odnosu na vrednost PTH u serumu koji je bio blago povišen, vitamin D snižen, kalcijum, fosfor i tireoidni hormoni u granicama referentnih vrednosti. Tireoglobulinska i tireoperoksidazna (TPO) antitela nisu nađena. Scintigrafija paratiroidnih žlezda pokazala je fiziološku distribuciju radiofarmaka. Posle šest meseci nadoknade D vitamina, nalaz PTH, D vitamina, kalcijuma, fosfora i TSH u serumu je bio u granicama referentnih vrednosti. Ovi nalazi ukazivali su da je opisana promena u levom lobusu odgovarala nefunkcionalnoj cisti paratiroidne žlezde. **Zaključak.** Ovaj prikaz pokazuje da cistične lezije u projekciji štitaste žlezde, tankih zidova, sa reverberacijom na ultrazvučnom pregledu, mogu da budu paratiroidne ciste. Prilikom aspiracije paratiroidnih cisti moguća je hiperkalcemična kriza koja može da bude životno ugrožavajuće stanje.

Ključne reči:

paratiroidne žlezde, bolesti; ciste; biopsija tankom iglom; hiperkalcemija.

Introduction

Parathyroid cysts have been relatively rare described in clinical practice, and till now, less than 300 cases have been reported in the literature. They are often confused with thyroid nodules¹. Parathyroid cysts could be diagnosed by ultrasound and verified by elevated parathyroid hormone

(PTH) in aspirated cystic fluid². First description of macroscopic characteristic of parathyroid cysts was described in 1880³. About 40% to 80% parathyroid lesions have been diagnosed by finding parathyroid cells in aspirated cystic fluid, about 8% to 30% are misdiagnosed as a thyroid lesion, and 8% to 16% have no enough cell elements for cytological diagnose^{4,5}. Cystic fluid is watery, colorless and looks as

lymph fluid, called "water from rocks"^{1,6}. Usually, there is no relapse after fine needle aspiration (FNA) and evacuation of cystic fluid after one-year follow-up⁷.

Case report

We examined a 40-year-old female with discomfort in the lower part of the anterior cervical region. In her left thyroid lobe there was elastic, palpable node, approximately 40 mm. An ultrasound examination revealed anechoic and oval-shaped lesion measuring 24 × 40 mm in the left thyroid lobe, with reverberation and without register of blood flow (Figure 1). In the right thyroid lobe there was a 5 mm hypochoic, colloid node.

Fine-needle aspiration was performed in order to evacuate the cystic fluid and to make cytology analyses. Fluid obtained by aspiration was watery, colorless, and it suspected to parathyroid cyst. In 13 mL of cystic fluid, the level of PTH was 766.22 pg/mL (serum reference range 15–65 pg/mL). Serum PTH was slightly elevated: 88 pg/mL [chemiluminescent microparticle immunoassay (CMIA), ARCHITECT ci8200, Abbot]. Serum calcium was 2.24 mmol/L, phosphorus 0.91 mmol/L and vitamin D was under the reference range: 12.6 ng/mL. Thyroid tests were normal, thyroid peroxidase antibodies (TPOAb) and thyroglobulin antibodies (TgAb) were not detected (Table 1).

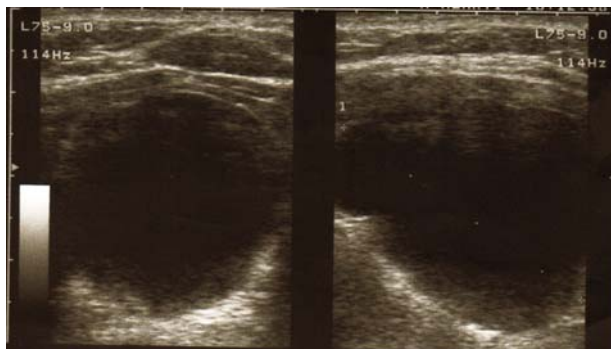


Fig. 1 – Ultrasound image of the left thyroid lobe – a cyst in the transversal section (left half of the panel) and longitudinal section (right half of the panel).

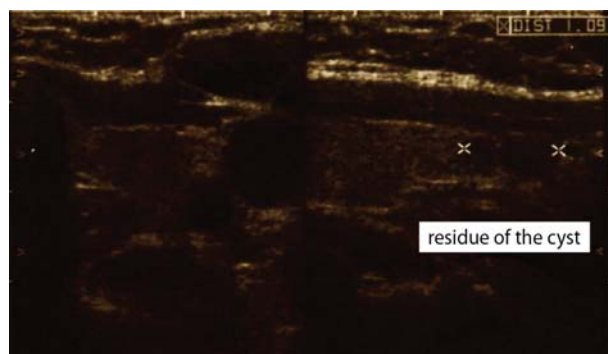


Fig. 3 – The area of the left lobe after repeated evacuation – a minimal residue of the cyst (transversal section on the left and longitudinal on the right panel).

Laboratory results		
Parameter	Baseline (reference range)	After 6 months
PTH (serum), pg/mL	88 (15–65pg/mL)	53.6
PTH (cystic fluid), pg/mL	766.22	
Calcium, mmol/L	2,24 (2,1–2,55)	2.13
Phosphorus, mmol/L	0,91 (0,79–1,42)	0.94
25 OHD, ng/ mL	12.6 (30–100)	33.2
TSH, μ U/mL	1.75 (0.35–4.94)	1.3
FT4, pmol/L	12.2 (9.0–19.1)	
TPOAb, IU/mL	2.4 (< 5.61)	1.4

PTH – parathyroid hormone; **TSH** – thyroid stimulation hormone; **FT4** – free thyroxine; **TPOAb** – thyroid peroxidase antibodies.

After one week ultrasound showed a residue of 2 mL of cystic fluid (Figure 2).

Cystic content was completely evacuated with repeated FNA. After the second aspiration ultrasound showed two hypochoic solid structure lesions, 4 and 5 mm in diameter, without cystic content (Figure 3).

Radionuclide parathyroid scintigraphy ⁶⁶⁶Tc99m methoxyisobutylisonitrile (MIBI) in 20, 60, and 120 min after applications indicated at physiological MIBI distribution (Figure 4).

After a 6-month vitamin D supplementation, serum calcium, phosphorus and PTH were normal, as well as serum vitamin D (Table 1). This finding was indicative that was a nonfunctional parathyroid cyst. Initially, the elevated PTH was a consequence of the low level of serum vitamin D.

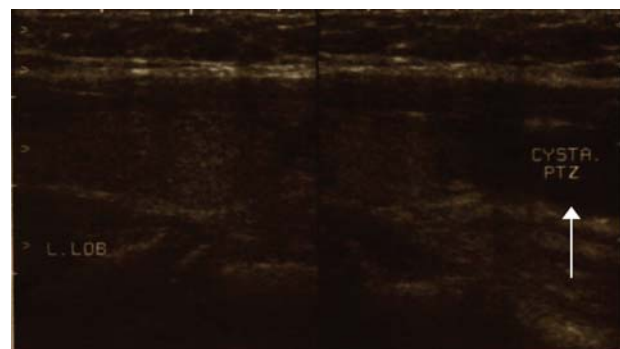


Fig. 2 – Ultrasound image in the longitudinal section – Directly to the bottom half of the left lobe is a remnant of the cyst.

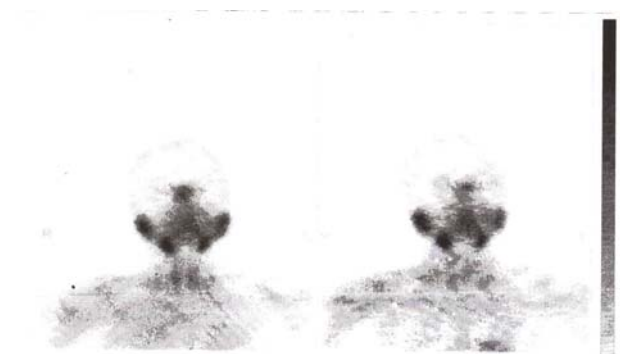


Fig. 4 – Radionuclide parathyroid scintigraphy [⁶⁶⁶Tc99m methoxyisobutylisonitrile (MIBI)] indicated a physiological MIBI distribution.

Discussion

Parathyroid cysts are often misdiagnosed as a solitary thyroid adenoma or nodular goiter. They could be nonfunctional or functional. In both of them, the level of PTH in cystic fluid is high⁶. Nonfunctional cysts are often located in the inferior parathyroid glands, particularly in the left inferior gland, while localization of functional cysts is unpredictable^{8,9}. They could be small, from some millimeters to more than 50 mm¹⁰. A true ontogenetic parathyroid cyst, from the remnants of the third or fourth branchial clefts, has thin wall, lined by secretory epithelium and contains watery cystic fluid. A cyst formed by the coalescence of micro-cysts may contain hemorrhagic fluid. Cystic degeneration of parathyroid adenomas could be presented as pseudocysts. Their content is a brown fluid and they are rather functional^{1,6,11}. Just a few cases of intrathyroidal parathyroid cyst reported till now. The latest was a case of primary hyperparathyroidism due to intrathyroidal parathyroid cyst which was confirmed by founding of elevated PTH in needle aspirate¹². Other etiologies of parathyroid cysts have been proposed without any supporting evidence¹³. Case report from 1965 was described that administration of high doses of calcium acetate, vitamin D2, vitamin D3 or extract of parathyroid gland can caused appearance of parathyroid cysts in rats^{14,15}. The both, nonfunctional and functional cysts have a high PTH content in cystic fluid. Sometimes, for PTH dosage, regarding Hook effect, cystic fluid must be in a diluted form⁶. In our sample of cystic fluid, the PTH level was tenfold

higher than the the reference serum range and dilution was not necessary. Functional cysts could be associated with high serum calcium, phosphorus and PTH, and they could appear spontaneously due to infarction or necrosis of parathyroid adenomas or could be worsening up to hypercalcemic crisis during or after FNA^{9,15}. Ultrasound with FNA is the first line of investigation approach. The routine morphologic and functional diagnostic tools in case of functional cystic adenoma, such as ultrasonography or (99m) Tc-sestamibi-scintigraphy, cannot distinguish between cystic parathyroid adenoma and carcinoma¹⁶. Elevated levels of PTH and C-terminal/mid-region of PTH itself are necessary for diagnose confirmation¹. Fine needle aspiration could be the first choice procedure for the diagnosis and treatment for nonfunctioning parathyroid cysts, but for recurrent cases ablation with 99% ethanol under ultrasound guidance can be a subsequent treatment modality¹⁷. Surgical treatment is recommended for functional and recurrent nonfunctional parathyroid cysts¹.

Conclusion

This case report elucidates the diagnostic pitfalls in fine needle aspiration of thyroid lesions. Also, some of thyroid cystic lesions with thin walls, and reverberation in ultrasound, have to be observed as a potential parathyroid cyst. These cysts require caution during diagnostic aspiration because of danger of hypercalcemic crises due to fine needle aspiration, which could be a life-threatening condition.

R E F E R E N C E S

1. Ciuni R, Ciuni S, Monaco G, Musmeci N, di Giunta M, Biondi A, Basile F. Parathyroid cyst. Case report. *Ann Ital Chir* 2010; 81(1): 49–52.
2. Cappelli C, Rotondi M, Pirola I, De ME, Leporati P, Magri F, et al. Prevalence of parathyroid cysts by neck ultrasound scan in unselected patients. *J Endocrinol Invest* 2009; 32(4): 357–9.
3. Mostafapour SP, True L, Futran ND. Clinical problem solving: pathology. Pathology quiz case 1: benign parathyroid cyst. *Arch Otolarynol Head Neck Surg* 2002; 128(5): 592–4.
4. Tseng F, Hsiao Y, Chang T. Ultrasound-Guided Fine Needle Aspiration Cytology of Parathyroid Lesions. *Acta Cytol* 2002; 46(6): 1029–36.
5. Agarwal AM, Bentz JS, Hungerford R, Abraham D. Parathyroid fine-needle aspiration cytology in the evaluation of parathyroid adenoma: cytologic findings from 53 patients. *Diagn Cytopathol* 2009; 37(6): 407–10.
6. Ghervan C, Goel P. Parathyroid cyst, a rare cause of cystic cervical lesion. Case report. *Med Ultrason* 2011; 13(2):157-160.
7. Suzuki K, Sakuta A, Aoki C, Aso Y. Hyperparathyroidism caused by a functional parathyroid cyst. *BMJ Case Rep* 2013; 2013: pii: bcr2012008290.
8. Ujiki MB, Nayar R, Sturgeon C, Angelos P. Parathyroid cyst: often mistaken for a thyroid cyst. *World J Surg* 2007; 31(1): 60–4.
9. Pinney SP, Daly PA. Parathyroid cyst: an uncommon cause of a palpable neck mass and hypercalcemia. *West J Med* 1999; 170(2): 118–20.
10. Wani S, Hao Z. Atypical cystic adenoma of the parathyroid gland: case report and review of literature. *Endocr Pract* 2005; 11(6): 389–93.
11. Codreanu C, Codreanu CM. Parathyroid cysts, a rare condition: a case report and review of the literature. *Chirurgia (Bucur)* 2011; 106(1): 127–9.
12. Datta D, Selvan C, Kumar M, Datta S, Das RN, Ghosh S, et al. Needle aspirate PTH in diagnosis of primary hyperparathyroidism due to intrathyroidal parathyroid cyst. *Endocrinol Diabetes Metab Case Rep* 2013; 2013: 130019.
13. Mazzeb H, Sippel RS, Chen H. Three large, functioning cystic parathyroid adenomas. *Endocr Pract* 2012; 18(1): 14–6.
14. Selye H, Ortica MR, Tuchweber B. Experimental production of parathyroid cysts. *Am J Pathol* 1964; 45(2): 251–9.
15. Zhu Y, Li N, Lu L, Chen S, Xing X, Meng X, et al. Hypercalcemic crisis due to a mediastinal parathyroid cyst diagnosed by ultrasound-guided fine needle aspiration. *Chin Med J* 2010; 123(24): 3731–3.
16. Wironski D, Wicke C, Böbner H, Lammers BJ, Pohl P, Schwarz K, et al. Presentation of 6 cases with parathyroid cysts and discussion of the literature. *Exp Clin Endocrinol Diabetes* 2008; 116(8): 501–6.
17. Sung JY, Baek JH, Kim KS, Lee D, Ha EJ, Lee JH. Symptomatic nonfunctioning parathyroid cysts: role of simple aspiration and ethanol ablation. *Eur J Radiol* 2013; 82(2): 316–20.

Received on June 24, 2014.

Accepted on October 23, 2014.

Online First September, 2015.